FACILITATING AMBULATION AFTER INCOMPLETE SPINAL CORD INJURY WITH IMPLANTED FES SYSTEM: A CASE REPORT

Gilles Pinault, Rudi Kobetic, Ronald Triolo, Lori Murray, Michelle Corado-Ahmed, Elizabeth Hardin, Jonathan Sakai, Stephanie Nogan, E.B. Marsolais, Chester Ho
Cleveland FES Center, Louis Stokes Cleveland VA Medical Center

Abstract

An 8-channel receiver stimulator (8-IRS) was implanted in an individual with C7 motor and C6 sensory incomplete spinal cord injury (SCI) (ASIA C) who could stand up on his own but could not initiate a step to walk. He was implanted bilaterally with intramuscular electrodes to recruit iliopsoas for hip flexion, vastus intermedius and lateralis for knee extension, tensor fasciae latae for hip flexion and abduction, and tibialis anterior and peroneus longus for balanced ankle dorsiflexion. An external control unit was programmed to provide power and stimulus timing information to the implant via a radio frequency coupling. After twelve rehabilitation sessions he was able to walk using a walker for support up to 140 ft at a time and up to 270 ft per session for a total of 53 minutes.

Introduction/Background

Many individuals with incomplete SCI can become functional walkers with FES since some of their motor, sensory, and proprioceptive functions are preserved [1, 2]. However, the motor deficits and stimulated responses exhibited in incomplete SCI indicate the necessity to customize the FES system to the particular needs of the individual. Although individual needs vary, functional systems that allow people with incomplete injuries to stand and walk can be created with existing FES technology.

In some individuals an exaggerated extensor tone provides safe standing, but compromises the ability to initiate a step voluntarily. In these cases, one or two channels of peroneal stimulation are necessary to inhibit extensor tone and help initiate a step [3]. These observations formed the basis for a prescriptive algorithm for the application of FES in this segment of the population. The least affected individuals, who could stand independently after undergoing strengthening of knee and hip extensors, needed only peroneal stimulation to initiate a step with the flexion withdrawal reflex [4]. In a majority of subjects, however, one leg was completely paralyzed while the other was sufficiently strong to allow safe and independent standing. This group required unilateral stimulation of the knee extensors in addition to the flexion withdrawal reflex for safe and effective walking [5]. Still others required bilateral knee extension with FES along with peroneal stimulation for stepping.

Surface, percutaneous and implanted FES technologies have all been applied to persons with incomplete SCI. Surface applications were used primarily for muscle re-strengthening, and hip/trunk stability was generally not addressed because of the difficulty in applying multiple electrodes [6]. In short-term feasibility studies, percutaneous systems provided enhanced control of the hip with good reliability and reproducibility of stimulation from day to day [7]. The purpose of this study was to implement the available implanted technology to provide practical clinical system for walking in incomplete SCI patients.

Methods

A 22 year old male with C7 motor and C6 sensory incomplete SCI (ASIA C) who could stand but could not initiate a step with either leg was evaluated for participation in this study. Initial test of muscle tone using modified Ashworth Scale showed marked increase in hip extensor tone during hip

flexion movement. The manual muscle test showed less than active movement against gravity in all muscles below the level of injury as shown in Table I.

	Right	Left	Function
C8	0	2	Finger Flexors
T1	0	1	Finger Abductors
L2	2	3-	Hip Flexors
L4-S3	2+	2+	Hip Extensors
L4-S1	1	2	Hip Abductors
L2-4	2+	2+	Hip Adductors
L3	3-	3-	Knee Extensors
L4-S3	1	1	Knee Flexors
L4	1	2	Ankle Dorsiflexors
L5	0	0	Long toe extensors
S1	1	2-	Ankle plantar flexors

Table I: Pre-op manual muscle strength.

A two months body weight supported (60%BW) Lokomat (Hacoma, SWE) gait training was initiated to assure stable baseline function. At the end of 16 sessions the subject was reevaluated for ability to walk. Unable to initiate a step on his own while supporting his weight, he underwent further evaluation with a programmable 8-channel surface stimulator to determine the most effective muscle activation pattern for walking. Based on these evaluations an 8-channel receiver-stimulator (8-IRS) [8] was implanted in the lower left abdominal area with intramuscular electrodes [9] tunneled subcutaneously to iliopsoas for hip flexion, to tensor fasciae latae for hip flexion and abduction, to vastus intermedius and lateralis for knee extension, and to tibialis anterior and peroneous longus for ankle dorsiflexion as schematically shown in Fig. 1. Six weeks of limited activity followed surgery to allow healing, then muscle strength was evaluated and gait training was initiated.

Results

The post-operative evaluation of muscle strength with FES showed good responses from all muscles as shown in Fig. 2. The subject was able to walk using a rolling walker

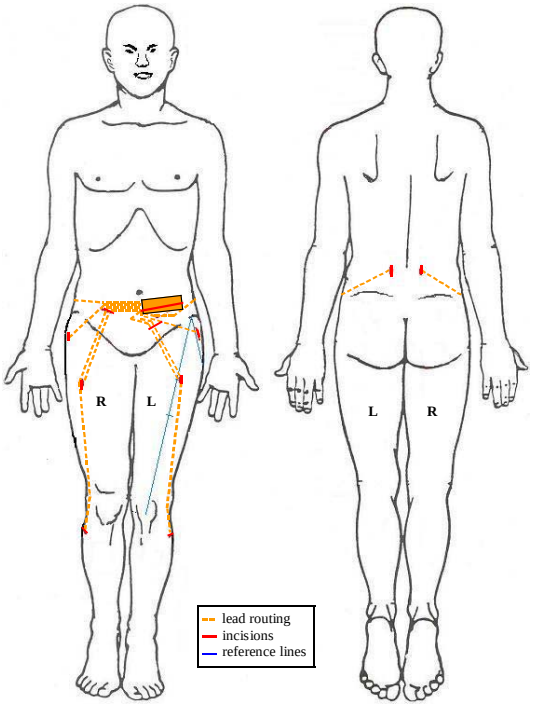

Figure 1. Schematic presentation of incision sites, electrode lead routing and location of implant and connection sites.

for support up to 140 ft at a time and up to 270

Figure 2. Knee extension and hip flexion combined with dorsiflexion.

ft within an hour session. His left and right volitional isokinetic knee extension moments

at 30deg/s were 17.8±6.0Nm and 23.9±8.5Nm, they were 41.2±1.4Nm and 27.8±2.2Nm with FES only and 43.9±3.9Nm and 27.0±2.9Nm when FES was combined with volitional effort, respectively.

Discussion/Conclusions

Figure 3. Subject walking with 8-IRS

While the results of this study are preliminary, the implantable FES system was shown to be effective in providing function above that possible volitionally that is repeatable from day to day with potential for continued improvement (Fig. 3). The implanted components are well tolerated (Fig. 4).

Currently the therapist controls the actuation of steps while a finger switch is being adapted to his limited hand function. In addition, EMG controlled step initiation is being explored to integrate his volitional and FES efforts.

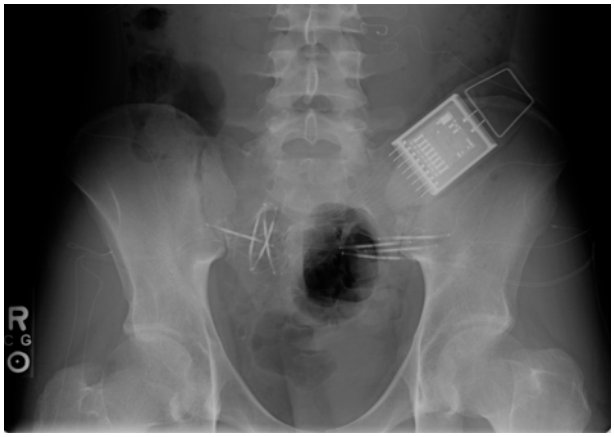

Figure 4. X-ray of 8-IRS and electrode connections.

References

1. Bajd T, et al. Restoration of walking in patients with incomplete spinal cord injuries by use of surface electrical stimulation-preliminary results. Prosthet Orthot Int 9:109-11, 1985.
2. Ferguson ACB, Granat MH. Evaluation of functional electrical stimulation for an incomplete spinal cord injured patient. Physiotherapy 78(4):253-256, 1992.
3. Bajd T, et al. Use of functional electrical stimulation in the rehabilitation of patients with incomplete spinal cord injuries. J Biomed Eng 11:96-102, 1989.
4. Kralj A, et al. Electrical stimulation of incomplete paraplegic patients. RESNA 4th Annual Conference, Washington D.C. 1981, pp 226-228.
5. Bajd T, et al. Assessment of functional characteristics relevant to FES application in incomplete SCI patients. In Popovic D (ed): Advances in External Control of Human Extremities IX. Belgrade, Yugoslav Committee for ETAN, 1987, pp 129-140.
6. Granat M, et al. The use of functional electrical stimulation to assist gait in patients with incomplete spinal cord injury. Disabil Rehabil, 14(2):93-97, 1992.
7. Stein RB, et al. Electrical systems for improving locomotion after incomplete spinal cord injury: an assessment. Arch Phys Med Rehab. 74:954-959, 1993.
8. Smith B, et al. An external powered, multichannel implantable stimulator for versatile control of paralyzed muscle. IEEE Trans Biomed Eng 34(7):499-508, 1987.
9 . Memberg WD, et al. A surgically-implanted intramuscular electrode for implantable neuromuscular stimulation system. IEEE Trans Biomed Eng 2(2):80-91, 1994.

Acknowledgments: This study is being supported by the Rehabilitation R&D Service of the Department of Veterans Affairs.