A pilot study of dysphagia by surface electrical stimulation on suprahyoid muscles area as neuromodulation

Kosei Mitsuhashi [1], Kazunori Seki [1], Naoshi Sato [1], Takahide Ogura [2], Hiroaki Yamamura [1], Yasunobu Handa [1]

[1] Department of Restorative Neuromuscular & Rehabilitation, Tohoku University Graduate School of Medicine, JAPAN
[2] Department of Medical Imaging Science, Tohoku University School of Medicine, JAPAN

E-mail:kosei@mail.tains.tohoku.ac.jp

Abstract

This pilot study examined the effect as neuromodulation of surface electrical stimulation (ES) on suprahyoid muscle area for dysphagia. The purpose of this study is to find out change of swallow function between before ES and after ES and to evaluate improvements as immediate effect and long term effect by ES.

Swallow function of two patients with dysphagia was investigated by videofluorography (VF). After ES, both patients could swallow some food quickly. Particularly, this effect continued several hours once ES had been done. This result suggests that ES can be one of the useful methods to improve swallow function in the patients with dysphagia.

1. INTRODUCTION

There are some reports on treatment using ES for dysphagia [1] [2]. The authors show that electrical stimulation provides dysphagic patients with improvement of swallow function. Major effects of this treatment for dysphagia are based on an assistive role of ES for movement of larynx during swallowing. On the other hand, it is well known that ES can modulate some spinal reflexes. Furthermore this effect usually continues at least several hours once ES has been done. It is regarded that such a phenomenon is one of types of neuromodulation. No one, however, has reported carry over effect of ES for swallow function. Therefore the effect of ES as neuromodulation of ES for dysphagia is not clarified. The purpose of this study is to find out change of swallow function between before ES and after ES and to evaluate improvements as immediate effect and long term effect by ES.

2. METHODS

Two patients with dysphagia (A: 90 years old male, B: 79 years old female) participated in this study. The cause of dysphagia was cerebrovascular accidents in A and collagen disease in B. VF was performed for these patients to estimate swallow function. Barium jelly was used for VF.

Figure 1 position of electrodes

Stimulation electrodes (Lintec Co. Ltd, Tokyo) were attached on the skin above the suprahyoid muscle (figure 1). Cyclic stimulation for 15min using bipolar rectangular pulse with 0.2msec duration was applied to each subject through a portable electrical stimulator (Lintec Co. Ltd, Tokyo). Stimulation frequency was 3Hz and the amplitude was set to the intensity just below pain threshold in each subject. The images of VF were recorded on a digital videocamera and analyzed on the computer system after conversion to digital data. Transit times of jelly and the change of distance between the hyoid bone and C4, the epiglottis and C4 during swallowing were analyzed using a software for motion analysis. (Dipp motion. Ditect Co Ltd, Tokyo). ES on the suprahyoid muscle area caused hyoid elevation. Movement of the hyoid bone synchronized with the stimulation signals during ES (figure 2).

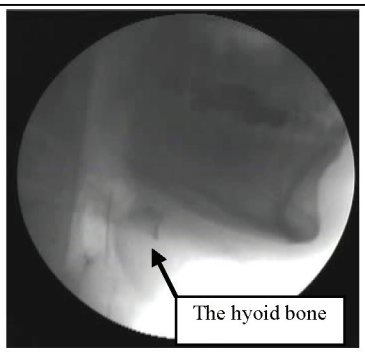

Figure 2 view of videofluorography in a healthy subject

3. RESULTS

Figure 3 shows the data in patient A on the change of distance between the hyoid bone and C4, the epiglottis and C4. These were compared between before ES and after ES. The peaks in each of the line (A) and (B) indicate maximum movement of swallowing just occurred at the timing of these peaks. Swallowing was also observed when the distance between epiglottis and C4 changed the most only after ES (←→at the line D). Movement of the hyoid bone and the epiglottis synchronized with swallowing after ES ((B)(D)). Doted line on B and D shows this synchronization. However, the hyoid bone and the epiglottis did not move simultaneously when swallowing before ES ((A)(C)). The same tendency was obtained in patient B.

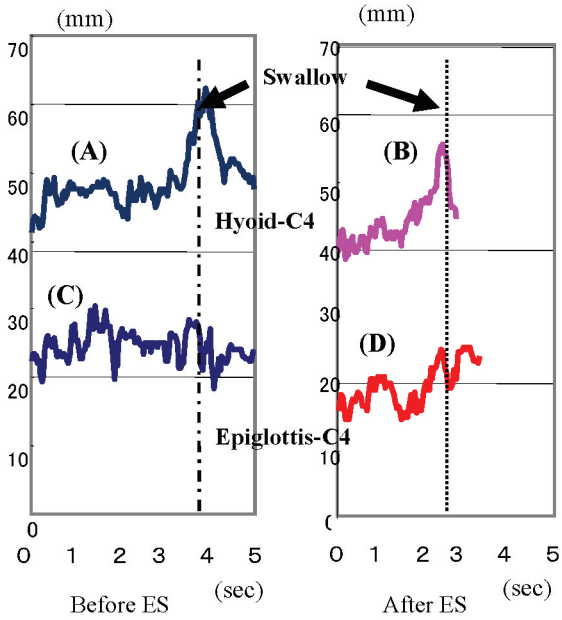

Figure 3 Change of distance of the hyoid bone-C4 and the epiglottis-C4 in before ES and after ES.

Figure 4 shows the change of transit times at swallowing. Transit times at swallowing of both subjects reduced after ES.

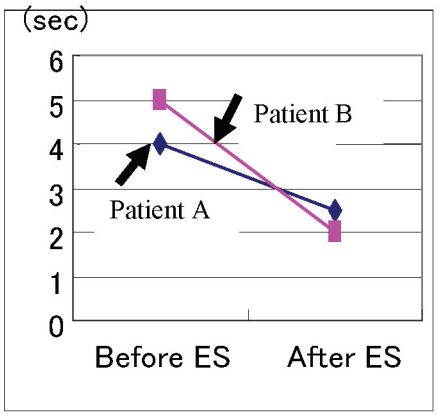

Figure 4 Change of transit times in vallecula epiglottica

There are some other findings that ES reduced pharyngeal pooling when swallowing and caused cough reflex though patient aspirated without tussiculation before this treatment.

4. DISCUSSION AND CONCLUSIONS

Our study had two major findings. First, we found reduction of transit times in vallecula epiglottica during swallowing in both patients. This effect maintain for several hours after ES. This result suggests that ES can be one of the useful methods to improve swallow function in the patients with dysphagia. Second, we found synchronized movement of the hyoid bone and the epiglottis after ES. The hyoid bone elevated without obvious swallow reflex during swallowing before ES. This is one of reasons that patients showed difficulty and had long a time at swallowing. Synchronized movement we found suggests that ES on the suprahyoid muscles area induced swallow reflex. Such a phenomenon may be explained by increase of sensory input to the central nerves system after ES. Further studies are needed to clarify the background mechanism of neuromodulation effect for dysphagia.

References

[1] Freed ML, Freed L, Chatburn RL, Christian M. Electrical stimulation for swallowing disorders caused by stroke. Respir Care 46(5):466–474, 2001

[2] Ludlow CL, Humbert I, Saxon K, Poletto C, Sonies B, Crujido L. Effects of Surface Electrical Stimulation Both at Rest and During Swallowing in Chronic Pharyngeal Dysphagia. Dysphagia, May 23,2006