Restoration of Functional Tenodesis Action in a Case of C5 Spinal Cord Injury by Means of Clinical Functional Electrical Therapy (FET)

Lee YH[1], Ju YM [1], Kim JR[1]

[1] Dept. of Rehabilitation Medicine, Wonju College of Medicine, Yonsei University, Republic of Korea

yumi_zxc83@hotmail.com

Abstract

The action of tenodesis in patients with a C5-6 SCI is very important for determining the functional level of performing the Activity of Daily Living (ADL). A clinical FET program combined with therapeutic activity program directly related to the ADL was provided to a patient with complete C5 SCI for 4 weeks. The extensor Carpi Radialis (ECR) and Flexor Digitorum Profundus/ Superficialis (FDP/S) and Flexor Policis Longus and Median nerve were stimulated simultaneously in an attempt to shape the tenodesis of the hand. The patient was also directed to move beans from one bowl to another with a spoon. The outcomes were measured in terms of the functional, physiological, and psychosocial aspects. The Action Research Arm Test (ARAT) and Spinal Cord Independence Measure (SCIM) were selected for the functional outcome. EMG analysis was performed to determine the physiological outcome. The Patient-Specific Functional Scale (PSFS) and semi-structured interview were followed for a psychosocial effect. The FET program in this study showed significant improvement in the physiological and psychosocial outcomes. The quality of the contraction of the remaining muscles was enhanced according to EMG analysis, which led to functional improvement showing better scores in the ARAT. In addition, the patient was quite satisfied with the FET program and reported that he performed better in feeding after the FET intervention.

1. Introduction

The upper extremity function of patients with a C5-6 spinal cord injury (SCI) is limited and strongly affects the performance of the Activity of Daily Living (ADL) compared with patients with C7-8 SCI. Patients with a C5-6 injury commonly have difficulty in performing the ADL with hand grasping such as feeding, brushing teeth, brushing hair etc. It is common for these patients to perform ADL assisted by using a hand splint, which holds the equipment to be used in the ADL. On the other hand, upper extremity training using tenodesis action is also common in occupational therapy for patients with a C5-6 injury. In addition, it has been demonstrated that the use of tenodesis action improves the performance of the ADL in C5-6 patients [1].

This study examined the effect of the early training with tenodesis assisted by electrical stimulation in a patient with a C5 SCI.

2. Methods

2.1. Subject

The subject participating in this FET program was a 33-year-old male inpatient, who had been injured since September, 2006. He had a closed fracture of the cervical spine and was neurologically diagnosed with a complete C5 SCI (ASIA-A). His cognition was assessed using the Mini-Mental State Examination (MMSE) on which he scored 30 out of 30, which was considered suitable for the FET program. He had been totally bed rested and only received cyclic FES on both wrist extensors for the first 4 months. No conventional therapy was provided due to his acute neurological condition. His first FET program was started in March of 2007 after being able to sit in a wheelchair for FET. The initial Manual Muscle Testing (MMT) was performed at this time (wrist extensor: Trace, finger flexors: Zero). He was right-handed before the injury but showed severe contracture of the right hand. The function of his left hand was better. Hence, his left hand was targeted for stimulation and training.

2.2. Stimulation Setting

A two channel and preset programmable stimulator [OdStock Ms2v2 (Microstim 2(v2))] was used. Mode 4 (20Hz, simultaneous contraction of two sets) was used for shaping the tenodesis grasp because a low frequency (20Hz) is commonly preferred for the small

wrist muscles in order to avoid muscle fatigue [2]. A total of four surface electrodes were applied to the Extensor Carpi Radialis (ECR) and Flexor Digitorum Profundus/ Superficialis (FDP/S) for one channel, and the Flexor Policis Longus and Median Nerve for the other channel. The tenodesis of the hand was produced by simultaneously stimulating these muscles and a nerve.

Figure 1- Application of Electrodes; feeding training with tenodesis by stimulating muscles and a nerve

2.3. FET protocol

Prior strengthening program

Since the patient could not obtain an adequate amount wrist extension, the selected stimulation for ECR was required. A prior strengthening program by cyclic FES was carried out twice daily for 30 min each. In addition, one session of cyclic FES for 30 min was continued even after the FET had begun.

FET

FET lasts for 30 min, five days a week. The patient practiced feeding with a built-up spoon. He was directed to grasp the spoon with the tenodesis action and transfer beans from one bowl to another when stimulation was applied. The FET program had been controlled for 4 weeks.

Figure 2- Diagram of therapeutic strategy

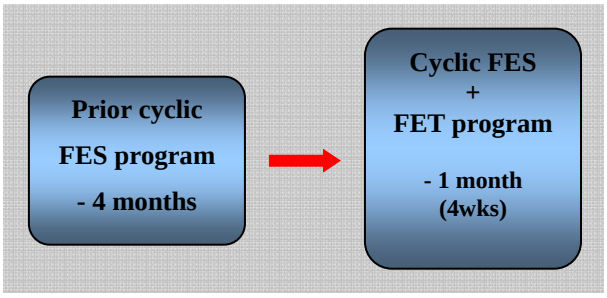

2.4. Outcome Measures

The outcomes were measured in three aspects functionally, physiologically, and psychosocially. The Action Research Arm Test (ARAT) and Spinal Cord Independence Measure (SCIM) were used to evaluate the functional outcome. For the physiological outcome, the Root-Mean-Square (RMS) and Median Frequency (MF) were calculated by EMG testing using the BIOPAC MP150 (BIOPAC Systems, Inc) and any changes in the fatigue index were measured from the MF value. The patient's self-perceived improvement in function was obtained using the Patient-Specific Functional Scale (PSFS) and through a semi-structured interview.

Table 1. Assessments used for outcome measure

Aspects	Assessments
Functional Outcome	- Action Research Arm Test - Spinal Cord Independence Measure (SCIM)
Physiological Outcome	- EMG
Psychosocial Outcome	- The Patient-Specific Functional Scale (PSFS) - Semi-structured Interview

3. Results

3.1. Functional Outcome

- Action Research Arm Test (ARAT)

The ARAT was divided into 4 sub-scales; grasp, grip, pinch, and gross movement subscale. The patient showed the most significant improvement in the grasp and grip subscale. In addition, he was able to grasp diverse sized blocks, a cricket ball, and a sharpening stone with some difficulty after the FET program, while he was unable to grasp any of these items before training. In addition, he was able to partially perform water pouring from one glass to another and displacing an alloy tube from one side of the table to the other.

Table 2. Result of ARAT at pre and post assessment

Action Research Arm Test	Initial	Follow-up
Grasp Subscale		
Block 10cm	0	2
Block 2.5cm	0	2
Block 5cm	0	3
Block 7.5cm	0	2
Cricket ball	0	2
Sharpening stone	0	2
Grip Subscale		
Pour water from one glass to another	0	1
Displace an alloy tube (2.25cm)	0	1

Displace an alloy tube (1cm)	0	0
Put washer over a bolt	0	0
Pinch Subscale		
Ball bearing of 6mm (1st & thumb)	0	0
Marble (1st finger and thumb)	0	1
Ball bearing of 6mm (2nd& thumb)	0	0
Ball bearing of 6mm (3rd & thumb)	0	1
Marble, 3rd finger and thumb	0	0
Marble 2nd finger and thumb	0	0
Gross Movement Subscale		
Hand behind head	1	3
Hand on top of head	2	3
Hand to mouth	2	3

* 3-performs the test normally; 2-complete the test bu takes abnormally long or has great difficulty: 1-performs the test partially; 0-cannot perform any part of the test

- Spinal Cord Independence Measure (SCIM)

The SCIM is an assessment for the gross level of the ADL. The patient was totally dependent in all self-care areas but obtained some independence in feeding and grooming after intervention. He was able to eat cut food using one adaptive device and hold a cup. In addition, he was also able to perform some tasks using adaptive devices relating to combing and brushing but required assistance in put on/take off devices.

3.2. Physiological Outcome

- Electromyograph

Surface EMG electrodes were attached to the ECR in order to measure the quality of the muscle. The initial and follow-up evaluations were performed before and after the 4 week FET program. The analysis revealed a significant increase in the RMS at the ECR after 4 week FET program (RMS in pretest: 0.051355 Volt, RMS in posttest: 0.064845 Volt). The resistance against fatigue during the consecutive muscle contraction was also improved showing a higher value in the Fatigue Index (FI) at the follow-up evaluation (FI in pretest: 0.652643 Hz, FI in posttest: 0.749826 Hz).

Figure 3- pre and post intervention result of EMG at Extensor Carp Radialis (ECR) during wrist extension contraction

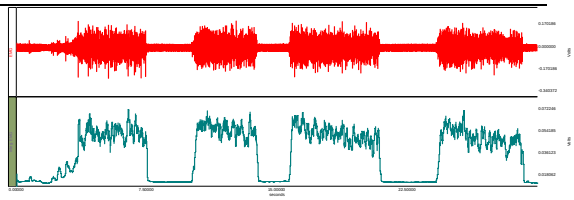

[Pre-intervention initial EMG test]-27th. 3. 2007

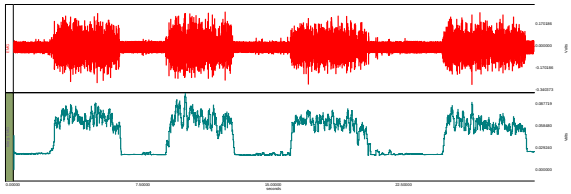

[Post-intervention follow-up EMG test]-26th. 4. 2007

3.3. Psychosocial Outcome

-The Patient-Specific Functional Scale (PSFS)

Three important activities that the patient was unable to perform as a result of his injury were identified through an initial interview, which was a part of this scale. It involved using a mobile telephone, feeding, and taking a note. He scaled his level of performance in these activities between 0 (unable to perform the activity) and 10 (able to perform the activity at the same level as before the injury or problem). At the initial stage, he scaled 2 point for using a mobile telephone, 0 points for feeding, 0 points for taking a note. After 4 weeks intervention, he scored 2, 3, 0 points respectively for the level of these functions.

Table 3. The result of PSFS

Activity	Initial	After 4 weeks
Using a mobile	2	2
Feeding	0	3 *
Taking a note	0	0

- Semi-Structured Interview

Several The patient was asked several questions regarding what was improved through the FET program.

1. He reported that he was able to grasp some equipment such as a spoon, a comb, a cup etc.

2. He answered that he became self motivated to some degree through the meaningful FET with feeding activities and showed increased motivation for not only the FET but for the other conventional therapies.

3. He said that his fingers are likely to be prevented from finger flexor contracture and he felt much smoother hand motion when performing some activities.

4. Discussion and Conclusions

FET is basically used to facilitate functional exercises in intervention and produces increased function, as well as an increase in independence and quality of life [3]. The aim of this study was to determine the effect of the FET program combined with therapeutic activity. First of all, the FET program was aimed primarily to fine improvement within the hand grasp. Therefore, it does not result in any advancement in the general ADL. However, the FET program in this study showed significant improvement in the physiological and psychosocial outcomes. The quality of the remaining muscles' contraction was enhanced as a result of EMG analysis, there was functional improvement showing better scores in the ARAT. Furthermore, the patient was quite satisfied with the FET program and reported that he performed better in feeding after the FET intervention. This study was a preliminary study with only one case. Therefore, a similar study with a larger sample will be needed to confirm this result.

References

[1] Pedretti LW, Early MB. Occupational Therapy: Practice Skills for Physical Dysfunction, 773-776, 2001.

[2] Mangold S, Keller T, Curt A, *et al.* Transcutaneous functional electrical stimulation for grasping in subjects with cervical cord injury. *Spinal Cord*, 43: 1-13, 2005.

[3] Popovic MR, Thrasher TA, Adams ME, *et al.* Functional electrical therapy: retraining grasping in spinal cord injury. *Spinal Cord*, 44: 143-151, 2006.